

¹Laboratory of Urogenital Carcinogenesis and Immunotherapy, University of Campinas (UNICAMP), Campinas-SP, Brazil
²Paulínia Municipal Hospital, Paulínia-SP, Brazil
³Innovare Biomarkers Laboratory, University of Campinas (UNICAMP), Campinas-SP, Brazil
⁴RECOD Laboratory, Institute of Computing (IC), University of Campinas, Campinas-SP, Brazil

Keywords: COVID-19, Immunotherapy, OncoTherad, Nanotechnology.

INTRODUCTION

SARS-CoV-2 infected patients exhibit the so called COVID-19 pandemic which is a respiratory disease characterized by progressive respiratory failure and may evolve to acute respiratory distress syndrome (ARDS), severe pneumonia, sepsis and septic shock with several kinds of dysfunctions (e.g. hepatic and vascular). Strong adaptive immune response to viral removal through IFN- γ demands early interferon type-1 IFN response. Furthermore, previous knowledge demonstrated cytokine dysregulation as a crucial attribute on SARS-CoV premature infection; the functional of CoV-cell recognition and type-1 IFN response may define the pro- or anti-inflammatory immune response and damage severity. Then, immunomodulators efficient of controlling cytokines initial response, such as effector cells enrolment and viral liberation, might be an excellent strategy against SARS-CoV-2. A synthetic nanostructured inorganic phosphate complex associated to a glycosidic protein, called OncoTherad, with immunomodulatory and antitumoral properties synthesized at the University of Campinas/ Brazil for the cancer's treatment. Taking into account the immunoprotective action of OncoTherad, and the function of the interferon signaling on COVID-19 infection control, it was searched the potential effect of this nano-immunotherapy on the management of SARS-CoV-2 infection in an individual diagnosed with moderate ARDS associated to COVID-19 infection.

METHODS

- Study protocol:** Case Report: A 78-year-old Brazilian man enrolled on the OncoTherad clinical trial (Brazilian Clinical Trials Registry – RBR-6swqd2) to treat BCG-refractory or relapsed HGNMIBC, arrived at Hospital Municipal de Paulínia in Brazil presenting COVID-19 symptoms. The patient reported dry cough, inappetence, coryza, and malaise, which appeared right after a cruise trip. The SARS-CoV-2 diagnosis was confirmed with local RT-PCR, IgM/IgG serological rapid screening and chest CT (Figures 1; 2-a, b, c). OncoTherad immunotherapy was resumed to treat the cancer condition with one intramuscular application. COVID-19 treatment regimen included oxygen therapy and standard chemotherapy regime. After 72 hours of hospitalization, diminished coryza, cough and absence of fever were observed. Oxygen therapy was maintained, and, after the 6th day of hospitalization, a significant improvement of pulmonary inflammatory condition. On the 8th day, oxygen therapy was removed. The patient was discharged on 10th day of hospitalization. A new chest CT was performed. Areas of ground-glass opacities were no longer observed (Figure 2-d, e, f). Moreover, treatment-related adverse events were Grade 1 or 2, such as pruritus and rash.
- SARS-CoV-2 testing:** The three parameters, such as, RT-PCR and rapid serological test positivity and chest CT findings confirmed the SARS-CoV-2 infection.
- Metabolic profiling using High Resolution Mass Spectrometry (HRMS) analysis:** Metabolites from each serum were extracted by tetrahydrofuran and methanol, followed by homogenization and centrifugation at 3400 rpm, 4°C for 5 minutes. Clear supernatant were diluted in methanol and ionized using formic acid. The final solution was directly injected in a HESI-Q-Orbitrap®-MS (Thermo, Bremen, Germany) and scanned with 140,000 FWHM of mass resolution on positive ion mode.
- Statistical analysis and pathway integration:** Mass spectral data of samples upon hospitalization admission and prior to discharge were checked using the XCalibur software (v. 3.0, Thermo Scientific).

RESULTS AND DISCUSSION

In spite of clinical findings, patient's evolution and recovery happen within a brief process (10 days) (Figure 2-d, e, f) than that described by former study. A 72 metabolites were classified based on m/z signals (features) ranked by $-3.5 < \log_2(FC) > 3.5$ and $p\text{-value} < 0.001$. Additional investigation of metabolites' relationship was grounded on the correlation network diagram created by MetaboAnalyst 4.0 software using KEGG compound ID (Figure 3-a, b). Entirely, our outcomes suggest extensive lipid dysregulation with pronounced glycerol-, glycerophospho-, sterol lipids and fatty acids metabolism disturbance. Mediators of arachidonic and linoleic acids metabolism, which play a role on inflammation were found (Figure 3-a). Beside this, patient clinical amelioration was characterized with upper levels of free fatty acids, acylcarnitines and phosphatidylglycerols, as previously reported on serum metabolome of recovered SARS-CoV patients. Interesting that the metabolism of sterol- and glycerolipids is disarranged after clinical condition enhancement, particularly on respect to triacylglycerols and cholesterol esters (Figure 3-b). Macrophages activate pathogen recognition through Toll-like receptors, which stimulate early response through cytokine signaling to virus liberation and prolonged storage of fatty acids as triacylglycerols.

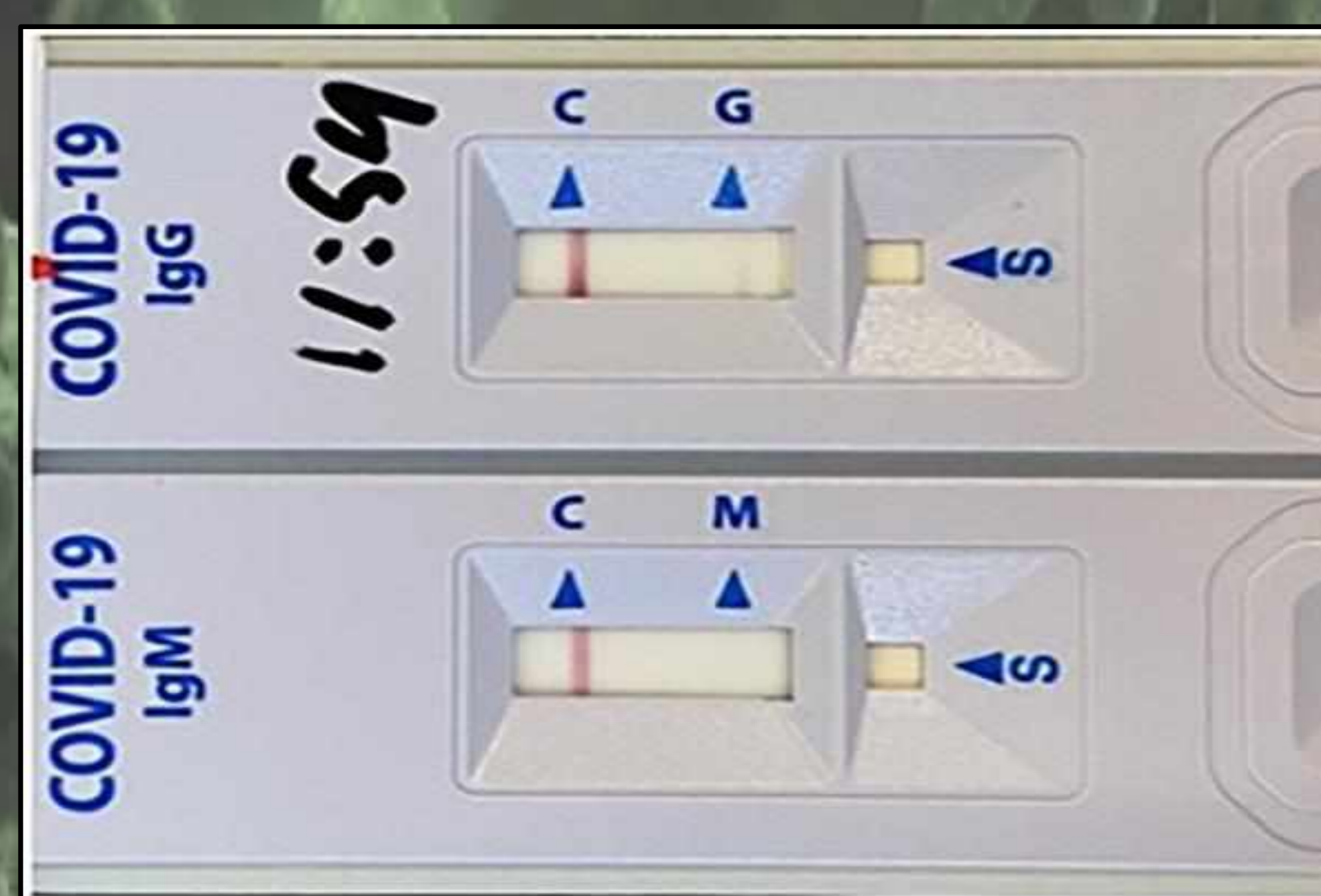

Figure 1: Rapid antibodies serological test (IgM/IgG) against SARS-CoV-2.

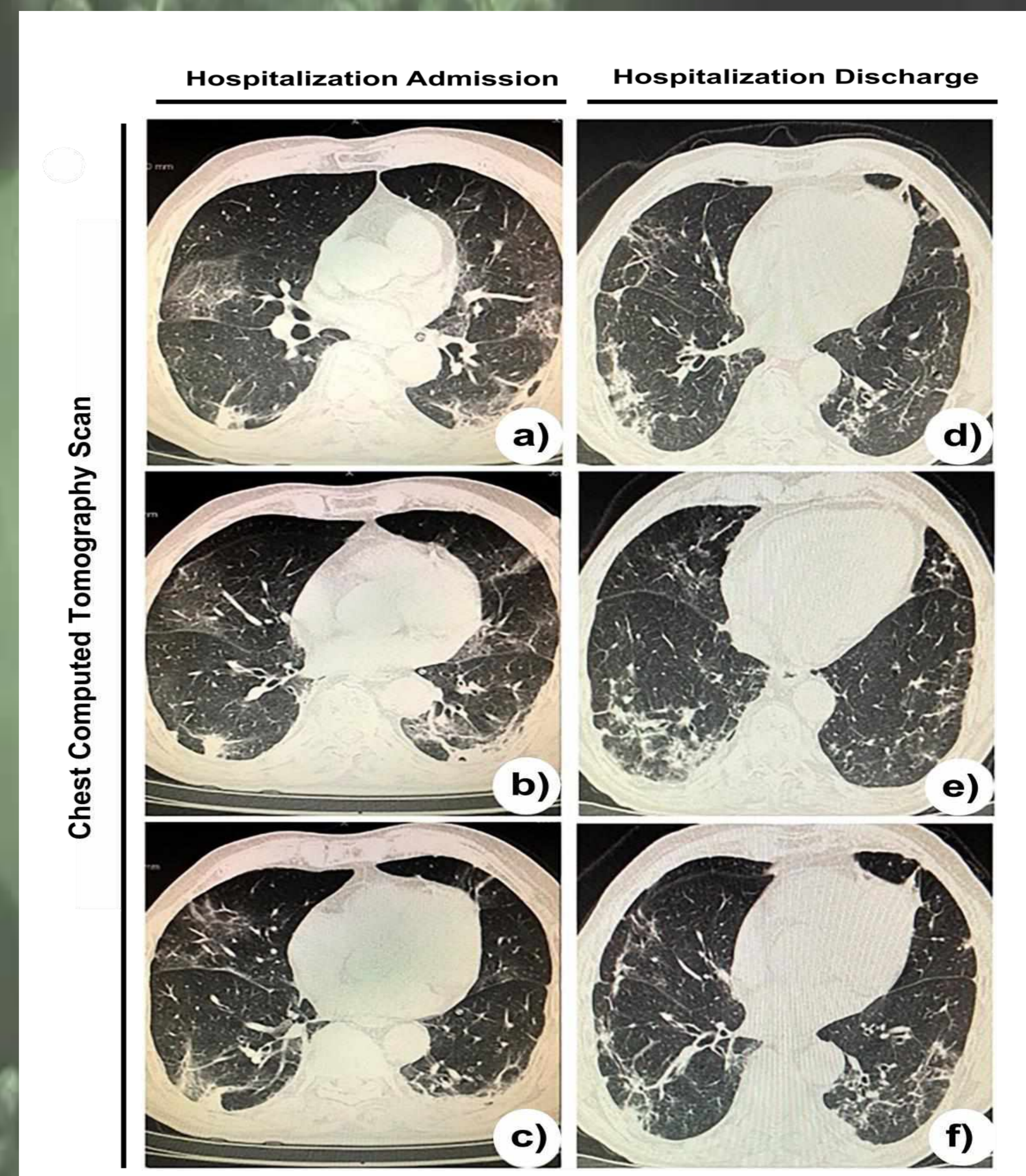


Figure 2: Chest CT alterations found in case patient on hospital admission (a, b, c) and on discharge (d, e, f). Areas of ground-glass opacities on lung parenchyma with bilateral distribution and predominance on right upper and middle lobes agree with active COVID-19 lung affection (a, b, c). This characteristic is not observed after patient clinical improvement, with predominance of periphery pulmonary consolidations and fibrous stripes (d, e, f).

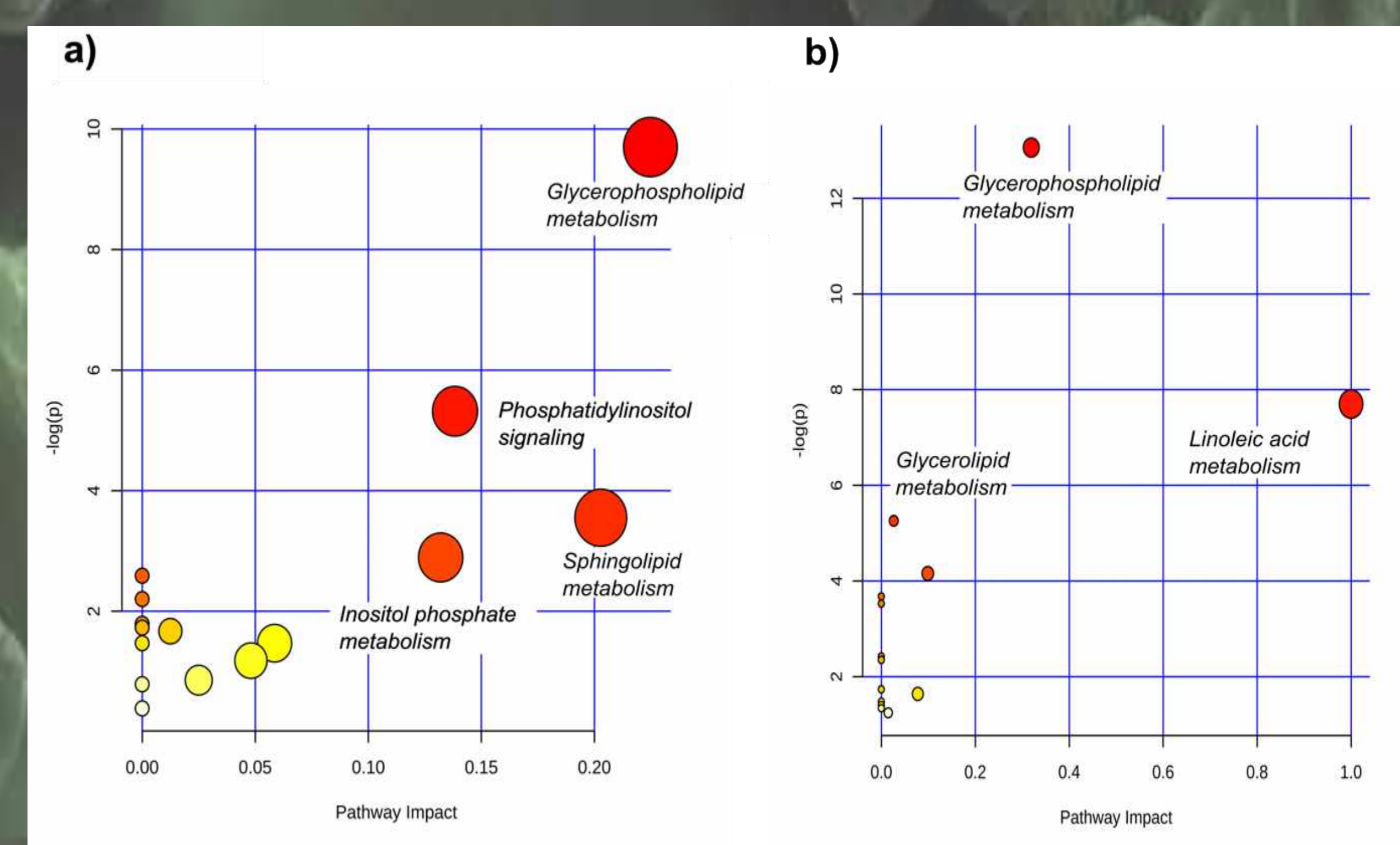


Figure 3: Clustering analysis used Ward's Clustering algorithm with Euclidean distance. Pathway matches are displayed in circles with importance based on p-value (Y-axis) and pathway impact (X-axis); h) important pathways with metabolites disturbances on patient's admission; i) metabolic profiling after patient's clinical improvement and on discharge.

CONCLUSIONS

All data presented in this research indicate that the OncoTherad appears as important effect as immunomodulator in SARS-CoV-2 infection]. Now an investigation with a cohort is in progress in order to understand OncoTherad immunomodulatory efficacy on SARS-CoV-2 infection management and its correlations with lipid metabolism and other found metabolites. Our data suggested that OncoTherad immunotherapy played a protective role against COVID-19 disease, preventing the infection evolution to a life-threatening condition. Then, due to the reliability shape and self-assurance of OncoTherad, the research of its prophylactic use or under the early stages of COVID-19 infection would be a relevant step to define the effectivity of OncoTherad for patient care in Brazilian hospitals during this pandemic.